
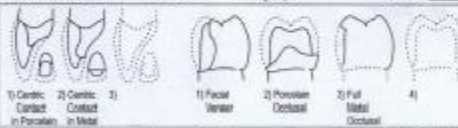




Variobase abutment implant work authorization example.

Fixed Implant Advance Payment BUSINESS OFFICE STAMP		 THE UNIVERSITY OF IOWA COLLEGE OF DENTISTRY & DENTAL CLINICS	
Student Doctor: John Doe Patient: Jane Smith (Axium ID) M <input checked="" type="radio"/> F Age 55 Date: 07/27/2018 Tooth #'s 5			
Lab: Williamsburg Dental Lab Account: _____ PO# _____ Total Charge _____ Remake: yes <input type="checkbox"/> no <input type="checkbox"/>		Return Date/Time Master Cast _____ Wax-Up _____ Framework _____ Blotup _____ Finish: 03/02/2018 AM	
Master Casts: <input checked="" type="checkbox"/> pour & gin <input checked="" type="checkbox"/> return to trim dies _____ mount _____ Restoration: _____ RFM <input checked="" type="checkbox"/> ACC _____ FCC _____ FPD _____ (range) Facial Margins: _____ mm metal collar _____ porcelain shoulder _____ disappearing Proximal Contacts: _____ metal _____ porcelain _____ Occlusal Contacts: _____ metal _____ porcelain _____ Post Core _____ Protrusive Contacts: _____ metal _____ porcelain _____ Lateral Guidance: <input checked="" type="checkbox"/> canine _____ group _____ tooth #'s _____			
			
Alloy: _____ HN _____ N _____ Base _____ Specific Material _____ PONTIC DESIGN: 			
Faculty Signatures: _____ Clinical Instructor: _____ Lab Tech: _____ Laboratory Authorization: _____ Date: 07/27/2018			
N# 39764			

Porcelain Characterization 															
Surface Texture: _____ Smooth _____ Moderate <input checked="" type="checkbox"/> Heavy Luster/Glaze: _____ High <input checked="" type="checkbox"/> Moderate _____ Dull/Low															
Shade: Vita 3D Guide: 2L1.5 Tab: _____															
1	2	3	4	5	6	7	8	9	10	11	12	13	14	15	16
32	31	30	29	28	27	26	25	24	23	22	21	20	19	18	17
Special Instructions															

Please fabricate a screw-retained single-tooth implant crown #5 as follows:

1. Reference attached abutment Rx form
2. Design and mill a monolithic, HT ingot zirconia crown #5:
 - A. Vita 3D shade=2L1.5; grey translucency in incisal 1/3, subtle halo
 - B. Photos sent electronically via eDossea
3. Lute completed crown to Variobase abutment
4. Establish light centric contacts on functional cusps
5. Maintain canine guidance in working laterotrusive movements (no excursive contacts)

- Thank You -